

Au4.6

a0005

Visual Areas in Humans

B A Wandell, S O Dumoulin, and A A Brewer,
Stanford University, Stanford, CA, USA

© 2008 Elsevier Ltd. All rights reserved.

p0005 Human visual cortex comprises 4–6 billion neurons that are organized into more than a dozen distinct functional areas. These areas include the gray matter in the occipital lobe and extend into the temporal and parietal lobes. The locations of these areas in the intact human cortex can be identified by measuring visual field maps. The neurons within these areas have a variety of different stimulus response properties. We describe how to measure these visual field maps, their locations, and their overall organization. We then consider how information about patterns, objects, colors, and motion is analyzed and represented in these maps.

p0010 Regions of cortex that respond powerfully to retinal stimulation are called visual cortex. In the human brain, the visual cortex is located in the occipital lobe and extends into the temporal and parietal lobes (Figure 1). In many mammalian species, visual cortex spans as much as half of the entire cortical surface area; in humans, the fraction is smaller – approximately 20%.

p0015 A key problem in visual neuroscience is to understand how information about patterns, objects, colors, and motion is analyzed and represented within visual cortex. One of the great advances of the past 50 years in our understanding of the processing of visual information has been the discovery of a basic functional architecture: In many species, visual cortex is divided into more than 12 distinct functional areas. The neurons within these areas differ in their stimulus response properties.

p0020 New developments in the past 15 years have allowed a multiplicity of distinct areas to be identified using functional magnetic resonance imaging (fMRI) in the intact human brain. The areas within human visual cortex are identified by measuring visual field maps. These are cortical regions that contain a topographic representation of the visual field; stimuli adjacent in the visual field evoke responses that are adjacent in visual cortex. Visual field maps can be identified in individual subjects with fMRI experiments that last approximately 1 h. Measurement of these maps is the most reliable approach to identifying a functional area within human visual cortex.

p0025 In this article, we first introduce the reader to the largest and best studied visual field map, primary visual cortex (V1). We describe how this map is measured

using fMRI, and we discuss the main features of the V1 map. We then summarize the positions and properties of 10 additional visual field maps. This represents our current understanding of human visual field maps, although this remains an active field of investigation, with more maps likely to be discovered. Finally, we describe theories about the functional purpose and organizing principles of these maps.

The Size and Location of Human Visual Cortex

The entirety of human cortex occupies a surface area on the order of 1000 cm² and ranges between 2 and 4 mm in thickness. Each cubic millimeter of cortex contains approximately 50 000 neurons so that neo-cortex in the two hemispheres contain on the order of 30 billion neurons. Human visual cortex includes the entire occipital lobe and extends significantly into the temporal and parietal lobes (Figure 1). Visual cortex contains on the order of 4–6 billion neurons.

The number of neurons in human visual cortex far exceeds the number in many other species that depend on vision. For example, the surface area of macaque monkey visual cortex is probably no more than 20% that of human visual cortex, although the cortical neuronal density is similar. This species difference in the number of cells in visual cortex cannot be explained by how these species encode the visual world. The monkey samples the retinal image at a higher resolution: There are 1.5 million optic nerve fibers from each eye in macaque and only 1 million such fibers in humans. The large size of human visual cortex is likely not a result of an increase in the supply of information but, rather, due to an increase in visual processing and the organization and delivery of information to other parts of cortex, such as those devoted to language and reading. Given these differences in visual cortex size, it would not be surprising that many features of human visual cortex are not present in closely related primate systems.

The Location of Primary Visual Cortex

The largest input to visual cortex projects from the retina via the optic nerve to the lateral geniculate nucleus (LGN) of the thalamus and then to primary visual cortex, commonly called V1. V1 is located in and around the calcarine sulcus, which can be found on the medial surface of both hemispheres (Figure 2a). The portions of left and right V1 that respond to signals near the vertical meridian are connected; the

2 Visual Areas in Humans

axons mediating these connections pass through the posterior aspect of the corpus callosum (the splenium).

The position of V1 can be identified on histological grounds. There is a stripe of heavy myelinated tissue in calcarine cortex that is apparent to the naked eye. This stripe was discovered by an Italian medical student, Francesco Gennari, in 1782, and the stripe is now called the stria of Gennari. Consequently, V1 is also referred to as the striate cortex, whereas other parts of visual cortex are collectively referred to as extrastriate cortex. **Figure 2b** is a cross-section through the calcarine cortex stained to reveal the myelination; note that the white matter is also strongly stained. The myelination runs through one of the cortical layers. The stria of Gennari terminates at the border of V1.

The discovery of the stria of Gennari was one of the first indications that cortex could be differentiated

into distinct regions. The association between this stripe and the projection zone of the LGN was not known at first. One hundred years after the discovery of the stria of Gennari, the Swedish neuropathologist Henschen showed that it is coextensive with the LGN projection zone.

Measuring Visual Field Maps

Anatomical

Until recently, researchers have had almost no access to measuring functional signals in the human brain. The development of fMRI resulted in an enormous outpouring of new data about the human brain. One of the first applications of this technology was to define the architecture of signals in human visual cortex. From extensive work in animal models, particularly macaque, it was known that visual cortex could be partitioned into a set of distinct visual field maps. Hence, an early focus in humans was to define the locations and properties of human visual field maps.

The organization of visual cortex is easily discernible on a flattened representation of the cortical surface. However, in humans, the cortex is highly convoluted, masking this topographic organization. In order to trace the borders of visual field maps, it is useful to create a representation that plainly exposes the signals in the sulci. This process is initiated by acquiring a set of anatomical images that have high contrast between the gray and white matter of the brain (**Figure 3a**). These data are processed to determine the location of the white matter (axon bundles) and the gray matter sheet that surrounds the white

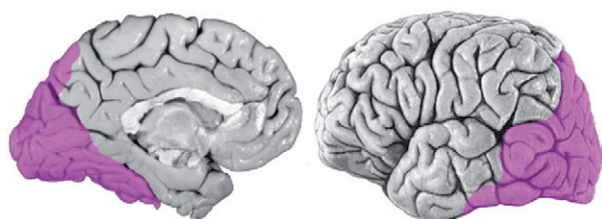

Figure 1 Human visual cortex. The extent of human visual cortex is indicated by the purple overlay shown on the medial and lateral views of a right hemisphere. Visual cortex occupies approximately 20% of the surface area of neocortex. Reproduced from Zeki S (2003) Improbable areas in the visual brain. *Trends in Neurosciences* 26(1): 23–26, with permission.

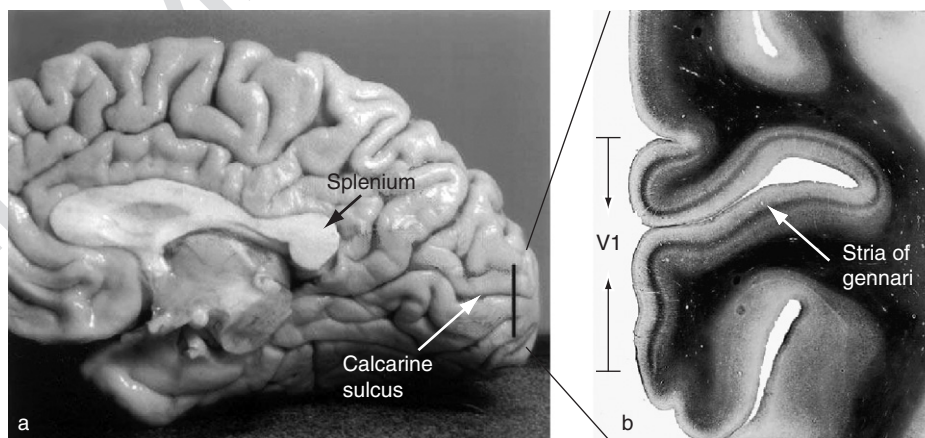


Figure 2 V1 and the stria of Gennari. (a) The location of right calcarine cortex and the splenium of the corpus callosum are shown. Primary visual cortex (V1) falls in and around the calcarine sulcus. Portions of right and left primary visual cortex are connected by axons that pass through the splenium. (b) Photograph of a coronal slice through the calcarine sulcus. This slice is stained for myelin (dark regions). Primary visual cortex is also called striate cortex because it is coextensive with the densely stained stripe that is the stria of Gennari. Reproduced from Andrews TJ, Halpern SD, and Purves D (1997) Correlated size variations in human visual cortex, lateral geniculate nucleus, and optic tract. *Journal of Neuroscience* 17(8): 2859–2868, with permission.

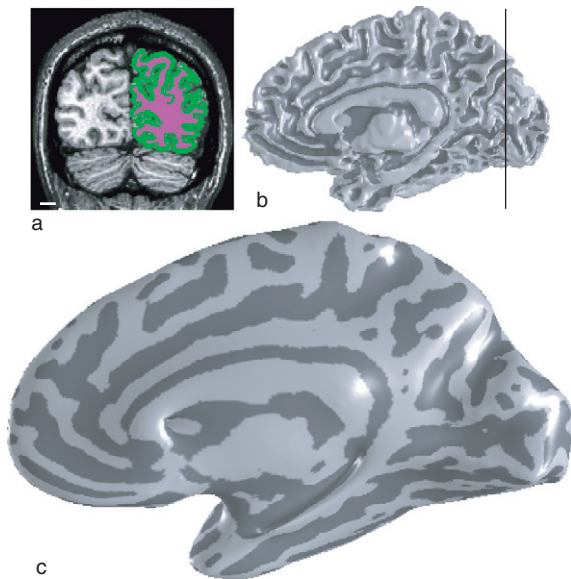


Figure 3 Cortical surface reconstruction and visualization. (a) A coronal slice of an anatomical MRI image is shown. Regions within the right hemisphere are colored to identify white matter (purple) and gray matter (green). (b) The white and gray matter segmentation identified in multiple slices defines a surface that can be reconstructed. (c) The cortical surface is 'inflated' or 'unfolded' to provide a convenient visualization of the cortical sheet within both sulci (dark) and gyri (light).

matter. Although there are several automated methods that achieve a good first approximation for this segmentation, careful work usually requires hand editing.

Once the gray matter voxels are identified, many automated tools are available to create a three-dimensional rendering of the boundary between the gray matter and the white matter (Figure 3b). Smoothing algorithms create a new 'inflated' representation of the surface (Figure 3c). In this format, the sulci are exposed so activation patterns can be tracked along the gyri (shown as light shading) and within sulci (shown as dark shading).

Functional

Visual field maps represent visual space in a unified, organized arrangement. These maps are often called retinotopic maps because their organization reflects the organization of the retinal image. Visual field maps can be identified by measuring which stimulus position in visual space produces the largest response in a particular section of visual cortex. There are many reasonable ways to do this experiment, but the most widely used method is to divide the measurements into two parts: measurements of eccentricity and angle with respect to the point of fixation. In one experimental session, one measures cortical responses

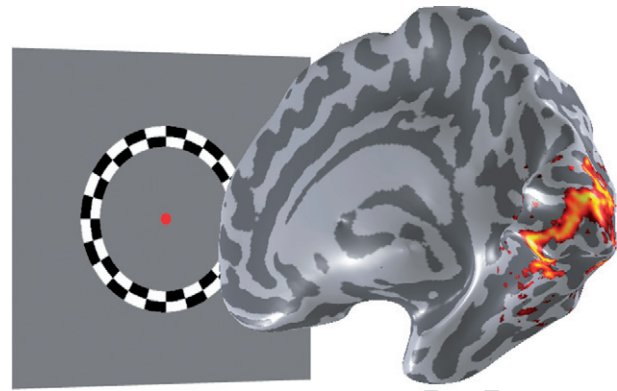


Figure 4 Traveling wave measurements using contrast rings. The functional activation elicited by a contrast ring surrounding fixation (red dot) is shown on an inflated representation of cortex. The peak response shifts smoothly from posterior to anterior calcarine as the ring grows from a small central ring to a large peripheral ring.

to a series of contrast rings, which measures the eccentricity component of the map (Figure 4); in a second session, one measures with a series of contrast wedges at different polar angles, which measures the angular component of the map.

This approach produces strong responses in human visual cortex. For example, a set of contrast rings of increasing size produce peak fMRI signals at a series of locations from posterior to anterior calcarine cortex (Figure 4)(Movie 1). The peak response shifts smoothly from posterior to anterior calcarine as the ring grows from a small central ring to a large peripheral ring.

By analyzing the timing of the peaks and troughs in the data, one can identify the visual field eccentricity that most powerfully stimulates each location in visual cortex. The information is commonly color coded to show the eccentricity that most effectively drives the response at each cortical location (Figure 5b). In a second experiment, using the rotating wedge stimulus, one can identify the angular direction that most effectively stimulates each cortical location (Figure 5c). Taken together, these two measurements define a visual field map, expressed in polar coordinates of eccentricity and angle. These measurements are combined into a single visual field map. The first three maps, V1–V3, are shown in Figure 5d.

The Human V1 Map

There are a few important characteristics to note about the V1 measurements. First, in the right calcarine sulcus, the most effective wedges are always located in the left part of the visual field (Figure 6).

This confirms a well-known anatomical projection: Signals from the left visual field project to VI in the right hemisphere. Second, stimuli in the upper visual field are most effective for neurons on the lower bank

of the calcarine (lingual gyrus), whereas stimuli in the lower visual field produce the greatest response on the upper bank of the calcarine (cuneus). Stimuli near the horizontal midline are most effective at stimulating cortex near the depth of the calcarine sulcus. Thus, the VI map is inverted with respect to the visual field but consistent with the retinal image. Finally, the central portion of the visual field stimulates posterior calcarine, whereas the more peripheral visual field stimulates anterior calcarine.

Note that there is considerably more cortical territory in V1 responding preferentially to stimuli within 2 or 3 degrees of visual angle than responding preferentially to stimuli in the periphery. The visual field map in V1 is a distorted version of the visual magnification. The term is unfortunate because the magnification is not introduced in cortex. Rather, the magnification begins at the level of the foveal cone photoreceptors in the retina, which are smaller and more tightly packed than peripheral cones. The number of retinal ganglion cells carrying information to the LGN and the number of V1 neurons transmitting the cone signals mirror the uneven cone density. Since the density of cortical neurons is approximately uniform, the differential number of neurons needed to process foveal and peripheral signals is manifest by an expanded surface area for foveal compared to peripheral representations in V1.

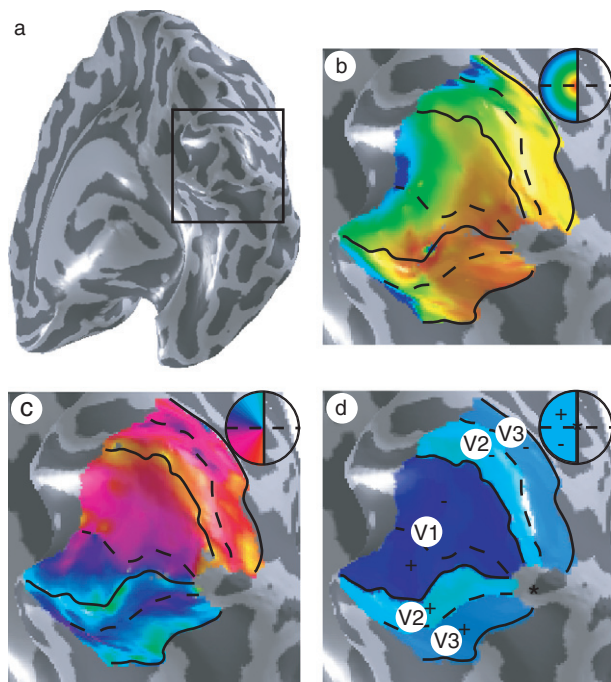


Figure 5 Polar angle and eccentricity measurements define visual field maps on the cortical surface. (a) The cortical surface of the right hemisphere is displayed from a ventroposterior view, emphasizing the occipital lobe. The position maps are displayed on the enlarged part of the occipital lobe, as indicated by the large black square. The maps for eccentricity (b) and polar angle (c) are shown. The insets indicate the color code that defines the part of the visual field that most effectively stimulates each cortical location. Visual field maps V1–V3 are identified from these eccentricity and polar angle measurements (d).

Extrastriate Visual Field Maps

The orderly representation of eccentricity and angular responses continues beyond the V1 map. The eccentricity representation in the surrounding cortex parallels that in V1 (Figure 5b). The polar angle representation in surrounding cortex is regular, but it

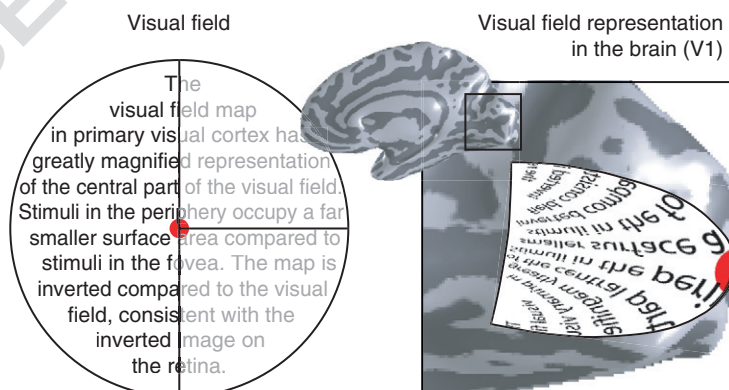


Figure 6 Schematic representation of the V1 visual field map. When one looks at the fixation point (red dot), the left part of the visual field evokes a response in right V1. Both the visual field and the V1 representation of this visual field are schematically illustrated. The V1 map preserves visual field topography, but relatively more cortical area is devoted to the central part of the visual field; this is called cortical magnification. Also, note that the lower visual field evokes activity on the upper bank of the calcarine, whereas the stimulus in the upper visual field evokes activity on the lower bank.

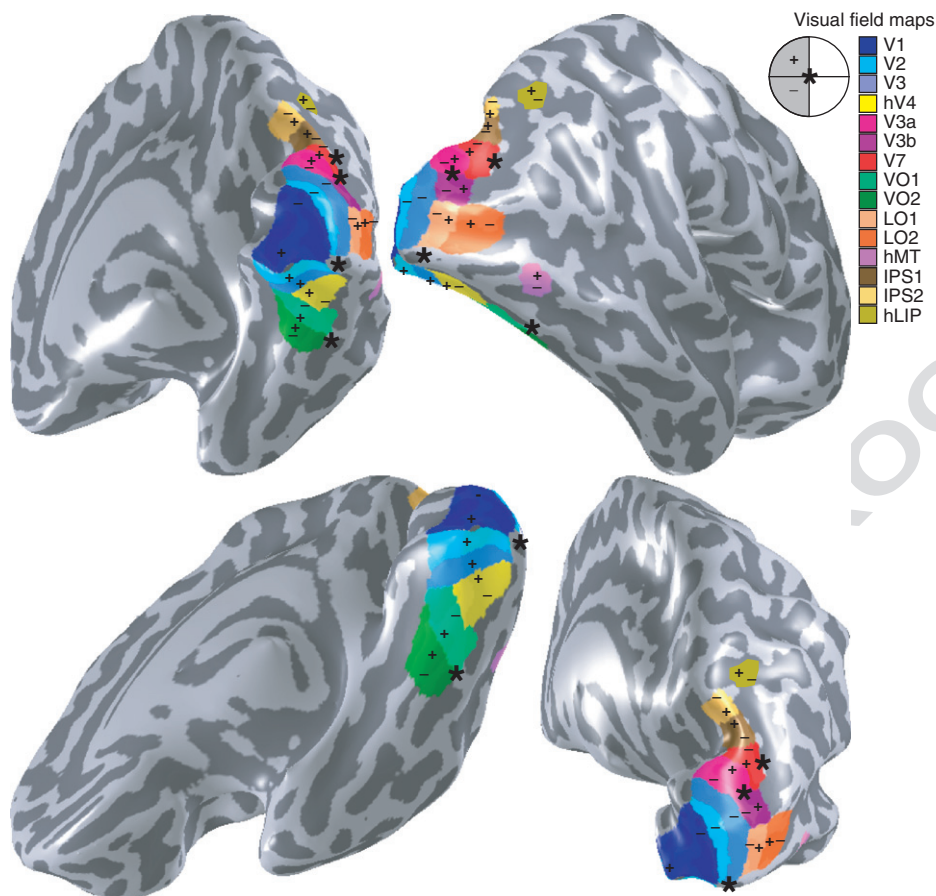


Figure 7 Visual field maps on a cortical surface. Currently identified visual field maps are shown on several views of a right hemisphere (see color legend). Fovea and upper/lower visual fields are indicated by the asterisk, plus, and minus symbols, respectively. The first visual maps are termed V for visual and a number, such as V1, V2, V3, and V3A, following the naming of apparent homologs in monkey. Doubts about the homology of the fourth visual map between monkey and human caused this map to be identified as hV4 (for human V4), and similarly for hLIP, a putative homolog to monkey lateral intraparietal sulcus. Historically, V5 is also referred to as medial temporal. Maps in lateral occipital cortex are numbered as LO-x, maps in ventral occipital are numbered as VO-x, and maps in the intraparietal sulcus are numbered IPS-x.

reverses direction: At the boundary of V1, the angular representation turns from the vertical meridian of the upper or lower visual field and progresses toward the horizontal representation (Figure 5c). The angular map reversal line is the functional signal used to define the boundary between the V1 and V2 maps.

The V2 map surrounds V1 (Figures 5d and 7). One section is located on the cuneus; this section is most effectively driven by signals in the lower visual field. The other section of V2 falls on the lingual gyrus; this section is most effectively driven by signals in the upper visual field. The V2 map is surrounded by a third map, V3. At the V2/V3 boundary, the angular representation reaches the horizontal and then reverses again into V3.

Careful mapping reveals the presence of at least 10 visual field maps (Figure 7). In many cases, these visual field maps are small maps which contain foveal representations distinct from the foveal confluence of the

V1–V3 maps. The maps shown here are largely agreed upon, although there is some debate concerning the specific organization of certain maps. It can be difficult to measure these maps for several reasons. Some of the maps are much smaller than the V1–V3 maps and thus are at the spatial resolution limit of conventional fMRI. Also, the size of neuronal receptive fields can be quite large in many of these areas, which makes measurements of the internal structure of these maps more difficult. As resolution and experimental methods improve, new maps will be identified, and our understanding of the known maps will be refined.

The presence of so many distinct visual field maps suggests that the map itself serves a functional purpose. The spatial organization of the maps may facilitate certain types of cortical computations. The internal structure of the visual field maps may simplify the connectivity needed for spatially localized visual

computations between neurons specialized for carrying such information as stimulus orientation, color, or motion. The simplification of axonal wiring is an important aspect of visual field map organization, given the remarkable observation that the axons in one cubic millimeter of cortex would extend over a length of more than 3 kilometers.

Visual Field Maps and Perception

How information is processed within visual field maps and the significance of this processing in terms of visual perception are central questions in visual neuroscience. The presence of multiple maps supports a view of visual cortex based on functional specializations. This view contrasts with the classic null hypothesis that cortex is equipotential or the theory that there is a canonical cortical circuit.

The dominant thinking for the past 30 years assumes that each extrastriate map represents a computational specialization. Furthermore, it is frequently asserted that these computations are associated with specific perceptual experiences. For example, a map on the lateral surface (V5/MT) is often described as a ‘motion center,’ and a set of maps on the ventral surface are often described as a ‘color center.’ The principle of associating maps with a perceptual experience is a form of the cortical specialization hypothesis. This framework has provided a scheme for scientists to discuss the significance of these maps, although this framework is far short of a computational theory.

The basis for the relationship between functional specialization and perceptual experience originated in neurological findings: Damage to specific extrastriate regions in ventral cortex leads to specific visual disabilities. Four cortical regions in which damage can produce a specific perceptual deficit are illustrated in Figure 8. The neurological deficits illustrated here are inability to recognize faces and interpret facial expressions (prosopagnosia or face blindness), loss of color vision of cerebral origin (cerebral achromatopsia), loss of motion perception (akinetopsia), and loss of the ability to read whole words (alexia). The neurological literature has focused on acquired forms of these deficits, but prosopagnosia also exists in a congenital (developmental) form; it is possible that the other dysfunctions may be discovered in developmental form as well.

The specificity of localized brain damage and perceptual deficits supports the functional specialization hypothesis for extrastriate maps. In contrast, the behavioral consequences of V1/V2 lesions are not usually functionally specialized. Damage to small (<5 mm) regions of V1 degrades vision generally

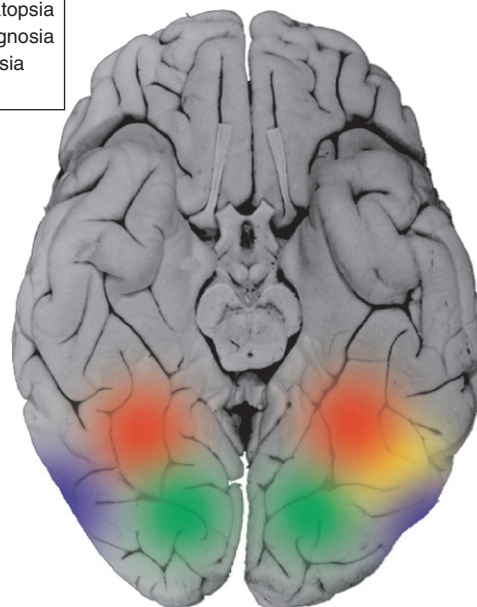



Figure 8 Regions of ventral visual cortex associated with specific neurological deficits. Regions implicated in specific visual impairments are indicated: the inability to recognize faces (prosopagnosia; red), to detect motion (akinetopsia; blue), to read words (alexia), and color blindness (achromatopsia; green). fMRI measurements aimed at isolating these functions typically yield strong activations at these corresponding cortical regions.

within the corresponding portion of the visual field. This suggests that the visual signals necessary for motion, color, recognition, and so forth are intermixed in neural signals in V1. Extrastriate regions, either innately or through learning, are specialized to interpret visual information needed in certain tasks. Hence, the architecture of visual cortex supports a mixed model in which certain cortical zones support a mixture of functions, whereas others are highly specialized.

Visual Field Map Clusters

Although the relationship between visual field maps and perceptual experience is an important scale to understand, the association between a map and perceptual experience does not provide a full model of visual processing, and it is unlikely that functional segregation by maps constitutes the only perceptual principle in visual cortex. For example, the dominant model of visual processing in retina, LGN, and V1 consists of several specialized and interleaved neural pathways within each structure. Starting in the retina, there are multiple parallel pathways specialized for conveying specific information about different aspects of the visual signal. Each pathway contains

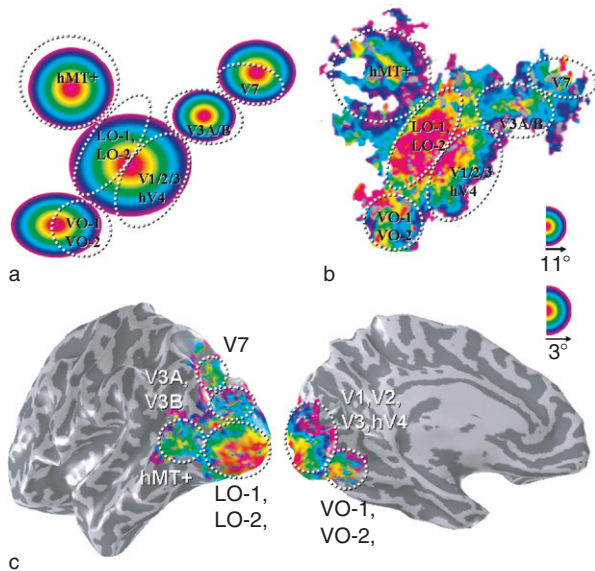


Figure 9 Visual field map clusters. (a) Schematic diagram of the organization of eccentricity representations in visual cortex. This diagram is based on measurements of these visual field map clusters, as shown on flattened cortex (b) and on a three-dimensional rendering of the inflated cortical surface (c). Each cluster contains several visual field maps that can be delineated based on the polar angle maps. VO, ventral–occipital; LO, lateral–occipital.

neurons that form a sampling mosaic covering the entire visual field. The neurons within these pathways are located near one another in retina and project to adjacent locations in the LGN and then primary visual cortex. The retina, LGN, and V1 can thus each be thought of as containing multiple, functionally distinct, superimposed visual field submaps.

This architecture is not likely to be completely abandoned in extrastriate cortex. In fact, there are already examples in which a single visual map contains distinct neural circuits that measure different aspects of the visual signal. An early and important example of functional heterogeneity can be found in motion-selective cortex (V5/MT), in which there is an orderly representation of both motion direction and binocular depth.

Just as functional specializations exist at a resolution finer than the map, specializations may also exist at a coarser scale. It was previously noted that the V1–V3 maps share a parallel eccentricity representation and are functionally divided by reversals in the angular representation. This same map architecture is present in several other clusters of maps, located in the ventral, dorsal, and lateral regions of visual cortex (Figure 9). Such organization of the individual maps into visual field map clusters may reflect a coarse level organization that follows specific functional

capabilities; visual field maps may be arranged in clusters when the neural mosaics within these maps serve similar computational goals.

Conclusions

The visual system is a valuable model system for neuroscience research because of the extensive information we have about the retinal encoding of light, the multiple pathways that communicate retinal information to cortex, and the distribution of the information from these pathways into maps in visual cortex. This information makes the visual system an excellent target for study beyond the core of vision science, including the neuroscience of development, plasticity, and consciousness.

The organization of visual pathways, maps, and clusters also may have application as an architectural model of general cortical processing. The parallels for other sensory systems are obvious and in many ways appear to be valid. For example, several distinct auditory maps with tonotopic organization have been demonstrated. It also may be that cognitive functions, such as decision making or the distribution of affective functions, are organized using a mixed architectural model in which certain regions contain general and others more specialized processing. To the extent that the cortical architecture of visual cortex matches that in other parts of cortex, we become more confident in results from both fields. Functional neuroimaging, which operates at a relatively coarse resolution of several millimeters to multiple centimeters, is well suited to uncovering structures at the scale of these visual maps or groups of maps.

In the near future, there will be many opportunities to link the functional neuroimaging measurements in quantitative ways to measurements at other resolutions – down to small (a few thousand) populations of cortical neurons. Advances in functional neuroimaging methods have already provided new information about the white matter pathways and long-distance connections between cortical zones. There will be substantial improvements in measurements of the molecular constituents of these cortical regions and in tracking changes in the molecular composition throughout development or following damage. Our current understanding of the architecture of visual cortex makes it a good system for developing these new methods and learning about cortical function broadly.

See also: Thalamic mechanisms in vision (00239); Visual attention (00242); Evoked potentials, recording methods (00318).

Further Reading

Hubel DH (1988) *Eye, Brain and Vision*. New York: Freeman.
Huettel S, Song A and McCarthy G (eds.) (2004) *Functional Magnetic Resonance Imaging*. Sunderland, MA: Sinauer.

Wandell BA (1995) *Foundations of Vision*. Sunderland, MA: Sinauer.
Zeki S (1993) *A Vision of the Brain*. London: Blackwell.

ELSEVIER AUTHOR PROOF