Neal Patel
Perry Alagappan

EE367 Project Proposal

Denoising of Abdominopelvic Computed Tomography Scans

Motivation:

Computed Tomography (CT) scans of the abdomen and pelvis of patients with a high body-mass index (BMI) often contain large amounts of noise. These patients may not be able to raise their hands above their head when lying in a CT machine, and thus keep their hands by their sides; the additional adipose tissue results in attenuated X-Ray beams, which in turn lowers the overall quality of the image. In order for radiologists to be able to provide an accurate diagnosis of medical conditions in such cases, the noise in scans must be mitigated.

Project Overview:

We will implement denoising techniques to help improve the visual quality of the noisy CT scans so that radiologists can make informed diagnoses. As noise for CT scans is generally Poisson-distributed, the method we will use is the Richardson-Lucy Algorithm with a variation of the prior (TV, NLM, etc.) to see which method provides the best results.

Timeline/Milestones:

February 12	February 20	February 27	March 1	March 11
Submit Proposal	Collect Dataset of Images for Analysis, Incorporate Feedback from Project Proposal	Complete Denoising Algorithms & Create Priors	Robust Testing of Images from Dataset w/ Algorithms/Priors	Final Project Presentation

Related Work & References:

Denoising CT images for high-BMI patients is a topic of several research studies. However, none have attempted to accomplish it using the Richardson-Lucy algorithm with TV/NLM priors. The

techniques we have seen reported for denoising such images include analytic reconstruction, image and projection space denoising, and iterative reconstruction.

1. Bariatric CT Imaging: Challenges and Solutions
2. The Obese Emergency Patient: Imaging Challenges and Solutions | RadioGraphics
3. Methods for Clinical Evaluation of Noise Reduction Techniques in Abdominopelvic CT

Image 1 below showcases the abdominopelvic region with significant amounts of noise (as we might see in a high-BMI patient), while Image 2 illustrates the same region with limited amounts of noise (as we might see in a normal-BMI patient).

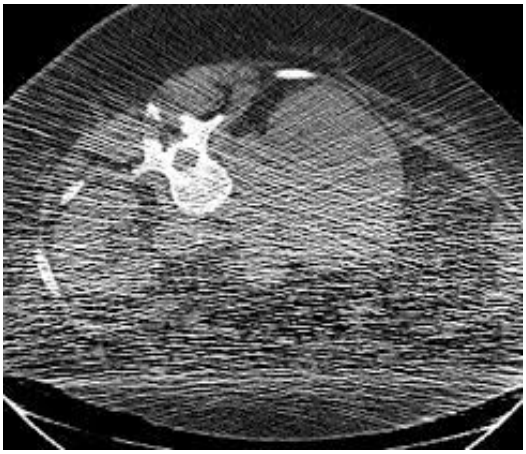

Image 1: Abdominopelvic Cavity (Significant noise is seen in striations across the image)

Image 2: Abdominopelvic Cavity (Limited noise is seen in striations across the image)